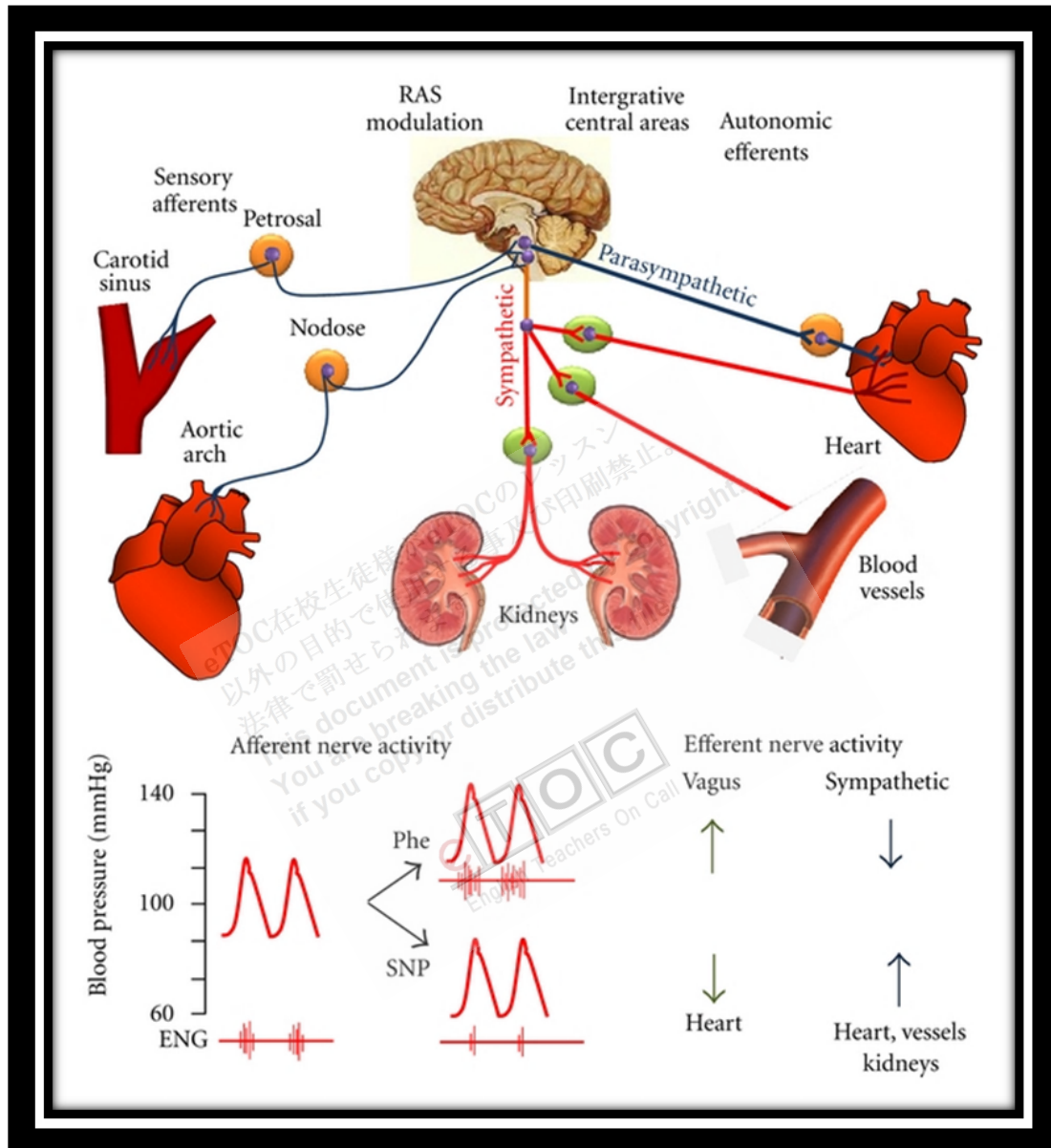


Renovascular Hypertension



<http://www.hindawi.com/journals/ijht/2012/968123/fig3/>

Renovascular hypertension is BP elevation due to partial or complete **occlusion** of one or more **renal arteries** or their branches. It is usually **asymptomatic** unless long-standing. A bruit can be heard over one or both renal arteries in < 50% of patients. Diagnosis is by physical examination and renal imaging with duplex ultrasonography, radionuclide imaging, or magnetic resonance angiography. Angiography is done before definitive treatment with surgery or angioplasty.

Renovascular disease is one of the most common causes of curable hypertension but accounts for < 2% of all cases of hypertension. Stenosis or occlusion of one or both main renal arteries, an accessory renal artery, or any of their branches can cause hypertension by stimulating release of **renin** from **juxtaglomerular cells** of the affected kidney. The area of the **arterial lumen** must be decreased by $\geq 70\%$ before stenosis is likely to cause hypertension. For unknown reasons, renovascular hypertension is much less common among blacks than among whites.

Overall, about two thirds of cases are caused by **atherosclerosis** and one third by **fibromuscular dysplasia**. Atherosclerosis is more common among men > 50 and affects mainly the proximal one third of the renal artery. Fibromuscular dysplasia is more common among younger patients (usually women) and usually affects the distal two third of the main renal artery and the branches of the renal arteries. Rarer causes include emboli, trauma, inadvertent ligation during surgery, and extrinsic compression of the renal pedicle by tumors.

Renovascular hypertension is characterized by high cardiac output and high peripheral resistance.

Symptoms and Signs

Renovascular hypertension is usually asymptomatic. A systolic-diastolic bruit in the **epigastrium**, usually transmitted to one or both upper quadrants and sometimes to the back, is almost **pathognomonic**, but it is present in only about 50% of patients with fibromuscular dysplasia and is rare in patients with renal atherosclerosis.

Renovascular hypertension should be suspected if diastolic hypertension develops abruptly in a patient < 30 or > 50; if new or previously stable hypertension rapidly worsens within 6 mo; or if hypertension is initially very severe, associated with worsening renal function, or highly refractory to drug treatment. A history of trauma to the back or **flank** or acute pain in this region with or without hematuria suggests renovascular hypertension (possibly due to arterial injury), but these historical findings are rare. Asymmetric renal size (discovered incidentally during imaging tests) and recurrent episodes of unexplained acute pulmonary edema or heart failure also suggest it.

Diagnosis

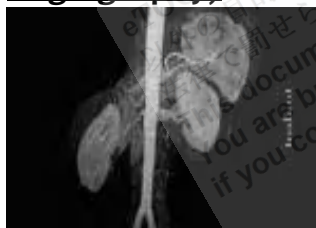- Initial identification with ultrasonography, magnetic resonance angiography, or **radionuclide imaging**
- Confirmation with renal angiography (also may be therapeutic)

If renovascular hypertension is suspected, ultrasonography, magnetic resonance angiography (MRA), or radionuclide imaging may be done to identify patients who should have renal angiography, the definitive test.

Duplex Doppler ultrasonography can assess renal blood flow and is a reliable noninvasive method for identifying significant stenosis (eg, > 60%) in the main renal arteries. Sensitivity and specificity approach 90% when experienced technicians do the test. It is less accurate in patients with branch stenosis.

MRA is a more accurate and specific noninvasive test to assess the renal arteries.

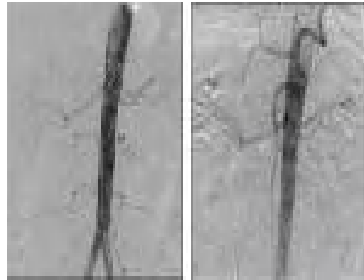Renovascular Hypertension (Magnetic Resonance Angiography)



Radionuclide imaging is often done before and after an oral dose of captopril 50 mg. The ACE inhibitor causes the affected artery to narrow, decreasing perfusion on the scintiscan. Narrowing also causes an increase in serum renin, which is measured before and after captopril administration. This test may be less reliable in blacks and in patients with decreased renal function.

Renal angiography is done if MRA indicates a lesion amenable to angioplasty or stenting or if other screening tests are positive. Digital subtraction angiography with selective injection of the renal arteries can also confirm the diagnosis, but angioplasty or stent placement cannot be done in the same procedure.

Renovascular Hypertension (Digital Subtraction Angiography)



Measurements of renal vein renin activity are sometimes misleading and, unless surgery is being considered, are not necessary. However, in unilateral disease, a renal vein renin activity ratio of > 1.5 (affected to unaffected side) usually predicts a good outcome with **revascularization**. The test is done when patients are depleted of Na, stimulating the release of renin.

Treatment

- Angioplasty sometimes with stent placement
- Rarely bypass graft

If the renal vein renin activity ratio is $> 1.5:1$, opening the obstructed renal artery using angioplasty with or without a **stent** usually relieves hypertension. Even when the ratio is lower, revascularization or removal of the affected kidney often cures hypertension.

Percutaneous transluminal angioplasty (PTA) is recommended for most patients, including younger patients with fibromuscular dysplasia of the renal artery. Placement of a stent reduces the risk of restenosis; antiplatelet drugs (aspirin, clopidogrel) are given afterward. **Saphenous vein bypass grafting** is recommended only when extensive disease in the renal artery branches makes PTA technically unfeasible. Sometimes complete surgical revascularization requires **microvascular techniques** that can only be done ex vivo with **autotransplantation** of the kidney. Cure rate is 90% in appropriately selected patients; surgical mortality rate is $< 1\%$. Medical treatment is always preferable to nephrectomy in young patients whose kidneys cannot be revascularized for technical reasons.

Atherosclerotic lesions respond less well to surgery and angioplasty than do lesions due to fibromuscular dysplasia, presumably because patients are older

and vascular disease is more extensive. Hypertension may persist, and surgical complications are more common. Surgical mortality rate is higher than that in young patients with fibromuscular dysplasia. **Restenosis** occurs within 2 yr after PTA in up to 50% of patients with renovascular atherosclerosis, especially when the lesion is located at the **ostium** of the renal artery, and, with stenting, in about 25%.

Without treatment, the prognosis is similar to that for patients with untreated primary hypertension. Medical treatment is inadequate without intervention to alleviate the stenosis, but aggressive medical treatment in **adherent** patients usually **ameliorates** and sometimes controls hypertension.

Reference: <http://www.merckmanuals.com>

eTOC在校生徒様がeTOCのレッスン
以外の目的で使用すること及び印刷禁止。
法律で罰せられます。
This document is protected by copyright.
You are breaking the law
if you copy or distribute this file.

eTOC
English Teachers On Call